

Motorcycle/Automobile Accident Injury Case Study
NUTSHELL SYNOPSIS

LIABILITY:

100% YOUR INSURED

Mr. At fault car driver was facing north. Police Officer Motorcyclist was southbound. Mr. At fault car driver made a sudden left turn directly into Officer Motorcyclist's motorcycle.

INJURY:

- **Full thickness tear of mid-to-posterior fibers of supraspinatus muscle with approximately 2.9 cm of muscle retraction**
- **Complete full thickness tear of infraspinatus muscle**
- **Partial tear of long head biceps muscle**

SURGERY:

- **Left shoulder arthroscopic subacromial decompression**
- **Left shoulder arthroscopic limited debridement of intra-articular biceps tendon**

1-877-BIKER LAW
LIABILITY

Defendant's liability in this matter is absolutely clear. A review of the police report indicates that on June 12, 2018 at approximately 3:59 p.m., our client, on-duty police officer Motorcyclist, was operating his motorcycle on southbound Southfield Road in Southfield, Michigan. He was traveling in the right turn lane of Southfield Road. As Officer Motorcyclist approached the entrance to the Applebee's restaurant parking lot abutting Southfield Road, your insured, was in the northbound inside lane of Southfield Road, waiting to make a left turn from northbound Southfield Road into the Applebee's parking lot.

As your insured attempted to make a left turn in front of him, Officer Motorcyclist immediately went into emergency braking, or maximum controlled braking, in an effort to avoid the crash. Notwithstanding, At fault car driver failed to yield the right-of-way and continued on with his left turn directly into Officer Motorcyclist's motorcycle, striking the tires of the motorcycle.

The force of impact to the motorcycle violently wrenched Motorcyclist's left shoulder as he attempted to right the motorcycle following impact, resulting in a serious injury to his left shoulder requiring surgery.



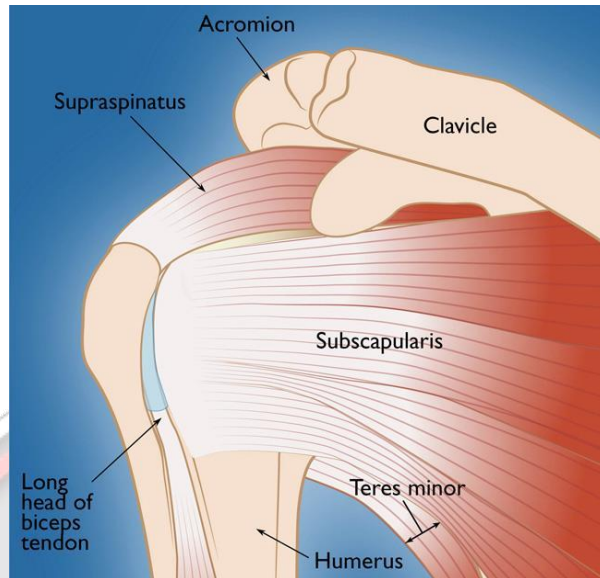
The Traffic Crash Report indicates that was noted for hazardous action and issued a citation for failure to yield the right-of-way. Motorcyclist received neither a hazardous action notation nor a citation. (See **EXHIBIT 1** – Traffic Crash Reports and Photographs)

1-877-BIKER LAW

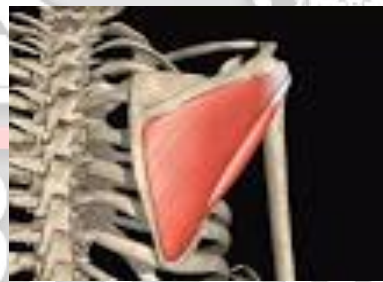ITEMIZATION OF INJURIES Resulting From The Crash 752

Motorcyclist's injuries on the police report were listed as "B," defined as "a non-incapacitating injury that is evidence to others at the scene." As a result of Mr Car Driver's negligence, Motorcyclist, sustained multiple injuries, including:

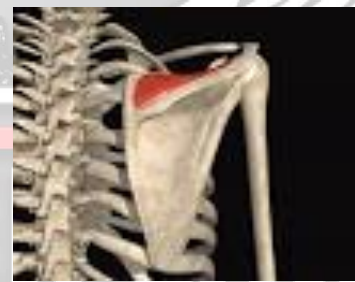- 1. Full thickness tear of mid-to-posterior fibers of supraspinatus muscle with approximately 2.9 cm of muscle retraction**
- 2. Complete full thickness tear of infraspinatus muscle**
- 3. Partial tear of long head biceps muscle**



Supraspinatus Muscle & Long Head of Biceps Tendon



Infraspinatus
Muscle & Tendon



Supraspinatus
Muscle & Tendon

Muscle is tissue that can contract to provide mobility and strength. Tendons are structures that connect muscle to bone.

HIGHLIGHTS OF MEDICAL RECORDS

Ascension Providence Hospital – Southfield [EXHIBIT 3]
6/12/2018

On June 12, 2018 was transported to the Emergency Department of Ascension Providence Hospital via the **Southfield Fire Department EMS [EXHIBIT 2]**. At the accident scene he complained of left shoulder pain, reported to EMS paramedics as pain at a level of 8/10 on movement. At the emergency room, he described throbbing left shoulder pain that worsens with movement of his arm or hand. He had tenderness to the lateral aspect of his left shoulder, limited range of motion with abduction, and difficulty placing his left arm above his shoulder.

Following physical examination, ER physician, , M.D., noted that he “**likely has a rotator cuff injury,**” and that “**There is no injury directly to the actual shoulder but likely transmitted from the impact after he was holding the handlebars.**” X-ray of the left shoulder revealed no fractures.

He was given pain medication and discharged with a diagnosis of shoulder sprain, defined in the discharge summary as “a stretching or tearing of the ligaments that hold a joint together.”

Medical doctor.O and Garden City Hospital / Radiology Associates [EXHIBIT 4]

The motorcyclist saw Dr. Stanley, family and sports medicine specialist, who ordered an MRI of left shoulder that was completed on June 15, 2018. The results of that MRI revealed:

1. Full thickness tear of mid to posterior fibers of supraspinatus with approximately 2.9 cm of muscle retraction;
2. Complete full thickness tear of infraspinatus muscle;
3. T2 [transverse relaxation] and PD [proton densities] hyperintense signal about the infraspinatus and teres minor muscle and within the posterior leaflet of teres minor which may represent myositis, edema, or possibly hemorrhage; and
4. Intact appearing glenoid labrum.

On June 18, 2018, Dr. reviewed the MRI report, wrote a script for off work and commented that, “[T]he patient will need surgery to the left shoulder.”

Sean F. , M.D. / The Core Institute / Bone and Joint Surgery Center of Novi [EXHIBIT 5]

Following MRI results, The motorcyclist attended an appointment with orthopedic sports medicine surgeon, Sean, M.D. on June 26, 2018. He was still complaining of constant, aching shoulder pain that awakened him at night. Dr. advised him that **the MRI shows a massive tear of supraspinatus and infraspinatus. Dr. believed the injury was “acute” since there was no significant muscle atrophy,** as he would notice if this were a chronic, long-standing injury. Although The motorcyclist had suffered a prior left bicep strain in approximately January 2015, that 2015 injury had long since healed. Dr. informed the motorcyclist that, given his age, his active job, and this acute tear, Dr. recommended surgical intervention to repair the acute injury to the shoulder sustained in the June 12, 2018 accident.

Surgery performed on July 26, 2018, consisted of left shoulder arthroscopic rotator cuff repair including subscapularis, supraspinatus and infraspinatus; left shoulder arthroscopic subacromial decompression (removal of bone tissue to increase the subacromial space to treat shoulder impingement); and left shoulder arthroscopic limited debridement of intra-articular biceps tendon. [Operative Report and photographs taken during surgery are included at **EXHIBIT 5.**]

Following surgery, Dr. ordered physical and occupational therapies, and wrote him off work for approximately three months. Motorcyclist returned to work on October 22, 2018, with restrictions from Dr. that he is not to use his upper extremity for at least six weeks. His next follow-up appointment with Dr. is scheduled for November 30, 2018. Until then, he remains on work restrictions.

All-Pro Physical Therapy / Peter Trifan, DPT [EXHIBIT 6]

Following surgery, The motorcyclist began a course of physical therapy in an effort to regain his prior level of function of 100% for difficulty with work, housework, or social activities. At his initial evaluation he complained of left shoulder pain at a level of 8/10 at worst, aggravated by lifting anything, pulling, raising his arm overhead, reaching back, lying flat, getting up out of bed, dressing and groom, cooking, carrying items. Pain was alleviated by pain medication, ice, heat, and avoiding activity altogether. At his recent re-valuation on September 24, 2018 following 18 sessions of PT, his symptoms had improved by approximately 20% and he was beginning to notice increased flexibility and range of motion. His shoulder continued to feel weak and he continued to have difficulty lifting and carrying heavy items. He continues to attend physical therapy three times a week and is continuing to make progress, but has not returned to his pre-accident status as yet.

LIFE AFFECTED

Since and as a result of the June 12, 2018 accident, Motorcyclist's life was and even remains significantly altered to the present time. At the time of this accident, The motorcyclist was on his way back to from a training session in Oakland County for his job as a motorcycle police officer for the. In addition to being a devoted, hard-working public servant, 46-year-old Motorcyclist is a devoted husband and father, who gladly participates with housework and cooking, enjoys attending his children's activities, and regularly plays catch with his son. He has been an avid motorcyclist, even outside of work.

Prior to this accident, The motorcyclist was looking forward to two scheduled motorcycle vacations, neither of which was possible following his painful shoulder injury. He was out of work entirely for about four months, and only recently returned to his job as a police officer, but only on restricted duty, with limited use of his arm. For an active, motorcycle officer, he finds sitting at a desk at the station, unable to ride with his partner, very confining, isolating, and wishing he could be back to his old routine and police officer duties. He has gained 20 pounds of unwanted weight because of his inactivity, and his physical relationship with his wife has been entirely adversely affected as a result of this accident. Also of significance is the fact that for a period of about two weeks, he experienced a period of coming off a brief addiction to oxycodone. He suffered through this period on his own rather than seek medical help. He describes this experience as "a dark couple of weeks for me."

CONCLUSION

Motorcyclist suffered serious, permanent injuries as a result of 's negligence resulting in the collision of June 12, 2018. After reviewing your file and the enclosed medical documentation, please contact me to discuss settlement of Motorcyclist 's claim.

